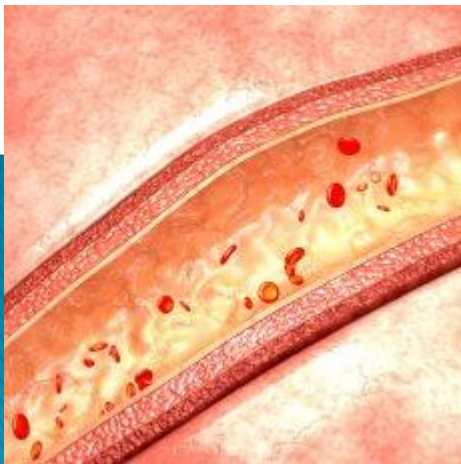


# Overt small bowel bleeding from small bowel ulcers due to microscopic polyangiitis

Gomes C, Ponte A, Pinho R, Rodrigues A, Silva JC, Afecto E, Correia J, Carvalho J

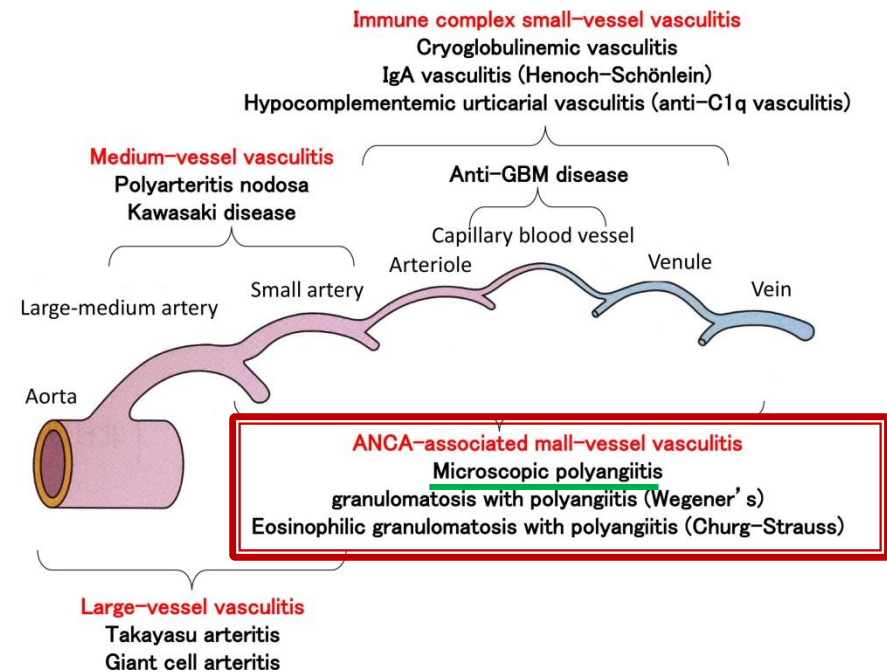
Serviço de Gastroenterologia, Centro Hospitalar Vila Nova de Gaia/Espinho, Vila Nova de Gaia

*22 de Janeiro 2021*



# Introduction

- ▶ ANCA-associated vasculitis (AAV) are systemic autoimmune diseases that affect small-to-medium-sized blood vessels.
- ▶ *Microscopic polyangiitis* is a pauci-immune AAV type.
- ▶ In myeloperoxidase antineutrophilic-cytoplasmic-antibodies (MPO-ANCA) (MPO-ANCA) stimulates neutrophil-induced cytotoxicity toward endothelial cells, leading to small-vessel wall inflammation, obliteration, and damage.
- ▶ *Microscopic polyangiitis*, typically involves the lungs and kidneys, with rare potential to involve the gastrointestinal tract, specially presenting with bleeding from a small bowel lesion.



# Case report

- ▶ ♀, 63 years-old
- ▶ Medical history:
  - CKD - *MPO-ANCA associated vasculitis*.
  - Medicated with acetylsalicylic acid



ER: Syncope + 4-day history of hematochezia

- ▶ Findings:
  - Hemoglobin 7.2 g/dL.
  - **Ileocolonoscopy:** dark blood, including on terminal ileum.
  - **Esophagogastroduodenoscopy:** no significant findings.

- **Video Capsule Endoscopy (VCE):** fresh blood in the distal ileum, without identifying the underlying lesion (figure 1)

- **Retrograde single-balloon enteroscopy (SBE):** segmental involvement with areas of congestive and ulcerated mucosa in the distal ileum (figure 2) - biopsies:



- **Histology:** ischemic process associated with **vasculitis** in the small bowel

Overt bleeding due to MPO-ANCA associated vasculitis in the small bowel

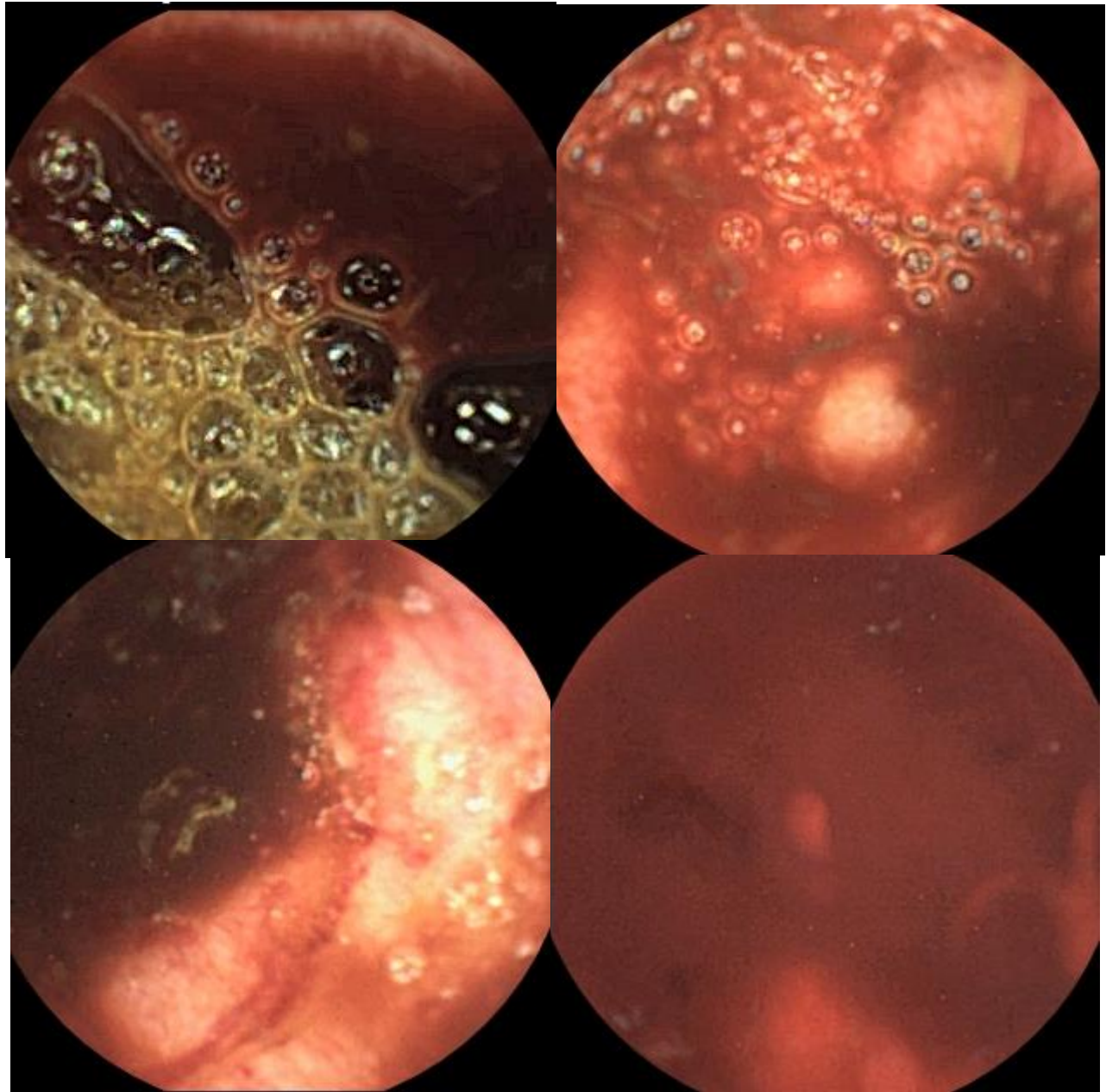


- ✓ **Treatment:** Intermittent pulses of cyclophosphamide and IV methylprednisolone

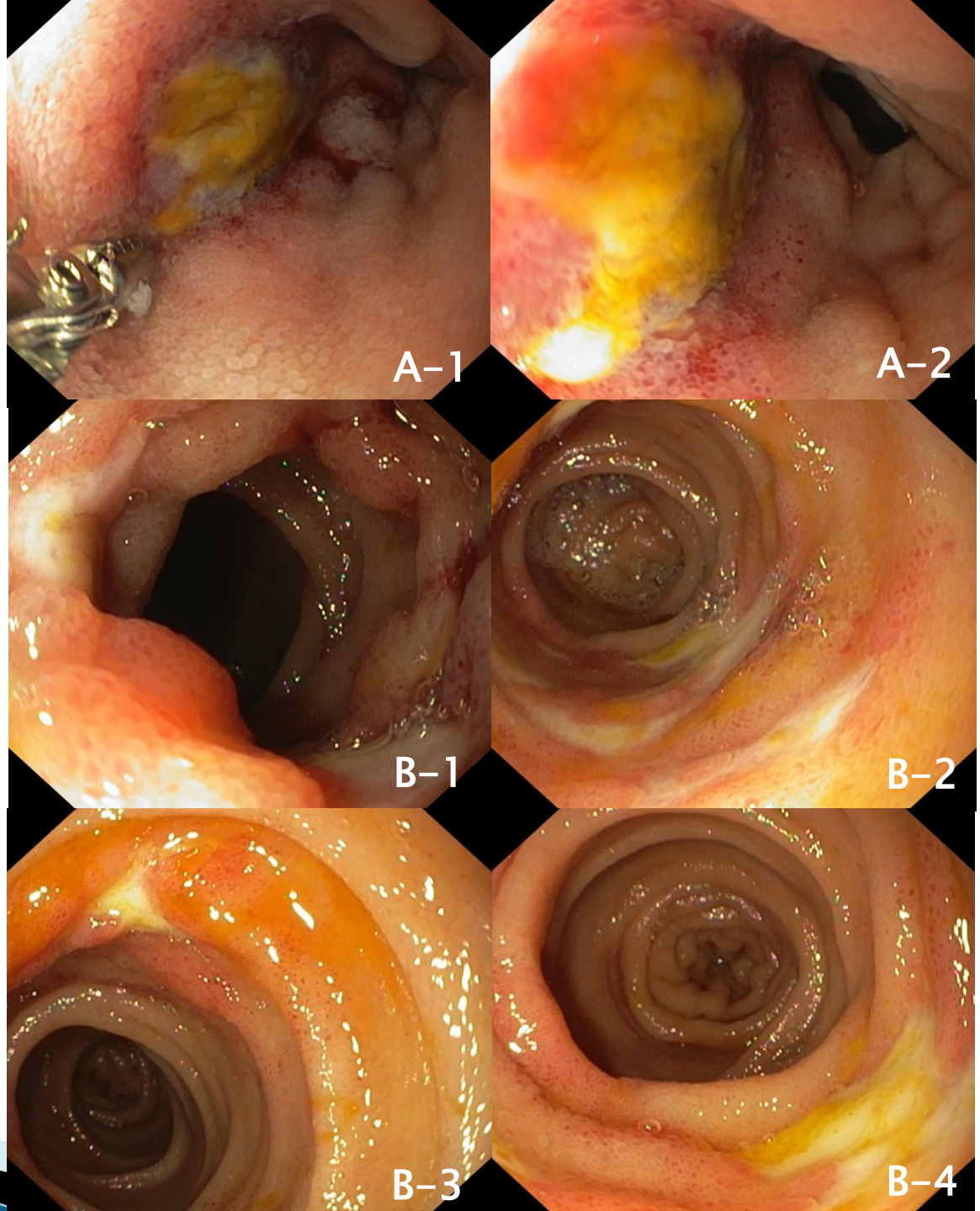
# VCE



Figure 1: Fresh blood in the distal ileum, without identifying the underlying lesion



# SBE



**Figure 2:** A (1-2): Terminal ileum ulcer;  
B(1-3): Segmental area with 5 cm extension of congestive and ulcerated mucosa.